

## Visual Impairment Network for Children and Young People (VINCYP)

# Optic Nerve Hypoplasia (including association with Septo-optic Dysplasia)

### What is Optic Nerve Hypoplasia (ONH)?

Optic nerve hypoplasia (ONH) refers to an abnormally small, underdeveloped optic nerve (ON). It is a congenital abnormality, thought to occur in the mid trimester of pregnancy in which a reduced number of axons form the optic nerve<sup>1</sup>. The earlier in pregnancy it occurs, the more severe the hypoplasia. It usually affects both nerves (75% of cases) but may be asymmetrical<sup>2</sup>.

### What is the significance of ONH?

ONH is probably the single most common ON anomaly, thought to occur in around 7/100,000 live births<sup>3</sup>. It is estimated to account for 12% of childhood blindness in the UK and may be associated with neurological or endocrine abnormalities, particularly **septo-optic dysplasia**. In bilateral cases, 46% have absence of the corpus callosum or septum pellucidum and 12% have panhypopituitarism. 27% of all children with ONH have endocrine abnormalities, the commonest of which is growth hormone (GH) deficiency<sup>4</sup>. Some studies suggest up to 75% have associated CNS abnormality.

### Risk factors and associations

Studies of children with ONH have suggested associations with young maternal age, first child, maternal diabetes, prematurity, periventricular leukomalacia and exposure to various toxins during pregnancy (alcohol, anticonvulsants, smoking, SSRIs, and cocaine) but no firm cause has been established.

It does occur in aniridia, anterior visual system tumours, with some brain malformations (holoprosencephaly, schizencephaly, porencephaly), in septo-optic dysplasia in combination with agenesis of the corpus callosum and/or pituitary insufficiency) and can also be inherited<sup>5</sup>.

### How does ONH present?

Optic nerve hypoplasia may present to the ophthalmologist with primary visual problems, or it may be suspected during endocrine or neurological assessment for associated conditions (eg neonatal hypoglycaemia, developmental impairment). Visual presentation depends on severity.

- Bilateral/severe ONH
  - Roving eye movements, blindness, sluggish pupil responses
  - May have see-saw nystagmus in septo-optic dysplasia
  - Delayed visual maturation
- Mild ONH
  - May be asymptomatic. Nystagmus and/or strabismus may be evident.
- Unilateral/asymmetric bilateral
  - Strabismus, unsteady fixation, relative afferent pupillary defect (RAPD)

## Visual Impairment Network for Children and Young People (VINCYP)

### What are the clinical features that define ONH?

The classic ophthalmological feature of ONH is the 'double-ring' sign where the true nerve size is represented by the inner ring.

The size of the disc can be estimated by calculating the disc-to-macula (DM) to disc diameter (DD) ratio. If DM/DD is over 3, this is suspicious of ONH, and if it is greater than 4, then ONH is very likely<sup>6</sup>.

Abnormal disc configurations with reduced nerve fibres can occur with sectoral ONH. The 'figure 8' disc is a variant of temporal hypoplasia, it occurs in conjunction with developmental suprasellar tumours. Hypoplasia of the upper part of the optic nerves is seen in children born to mothers with diabetes mellitus.

Ex-premature babies with periventricular leucomalacia (PVL) may show abnormal ON cupping as a variant of optic nerve hypoplasia in normal sized optic discs with reduced axonal numbers. In this case the mechanism is retrograde transsynaptic degeneration occurring after 28 weeks<sup>7</sup>.

### MRI features

Children with ophthalmoscopic appearances of ONH have reduced cross-sectional intracranial ON diameters. A cross-sectional area of <2.9mm<sup>2</sup> in a child over 12 months of age (by which time the ON has achieved most of its adult size) suggests ONH<sup>8</sup>.

### Visual evoked potentials (VEP)

The VEP can be reduced in severe ONH with reduced acuity. Reduced VEP can be predictive of a poor visual prognosis. The flash ERG is usually normal<sup>9</sup>.

**Reviewed:** May 2022

**Review Date:** May 2025

#### NOTE

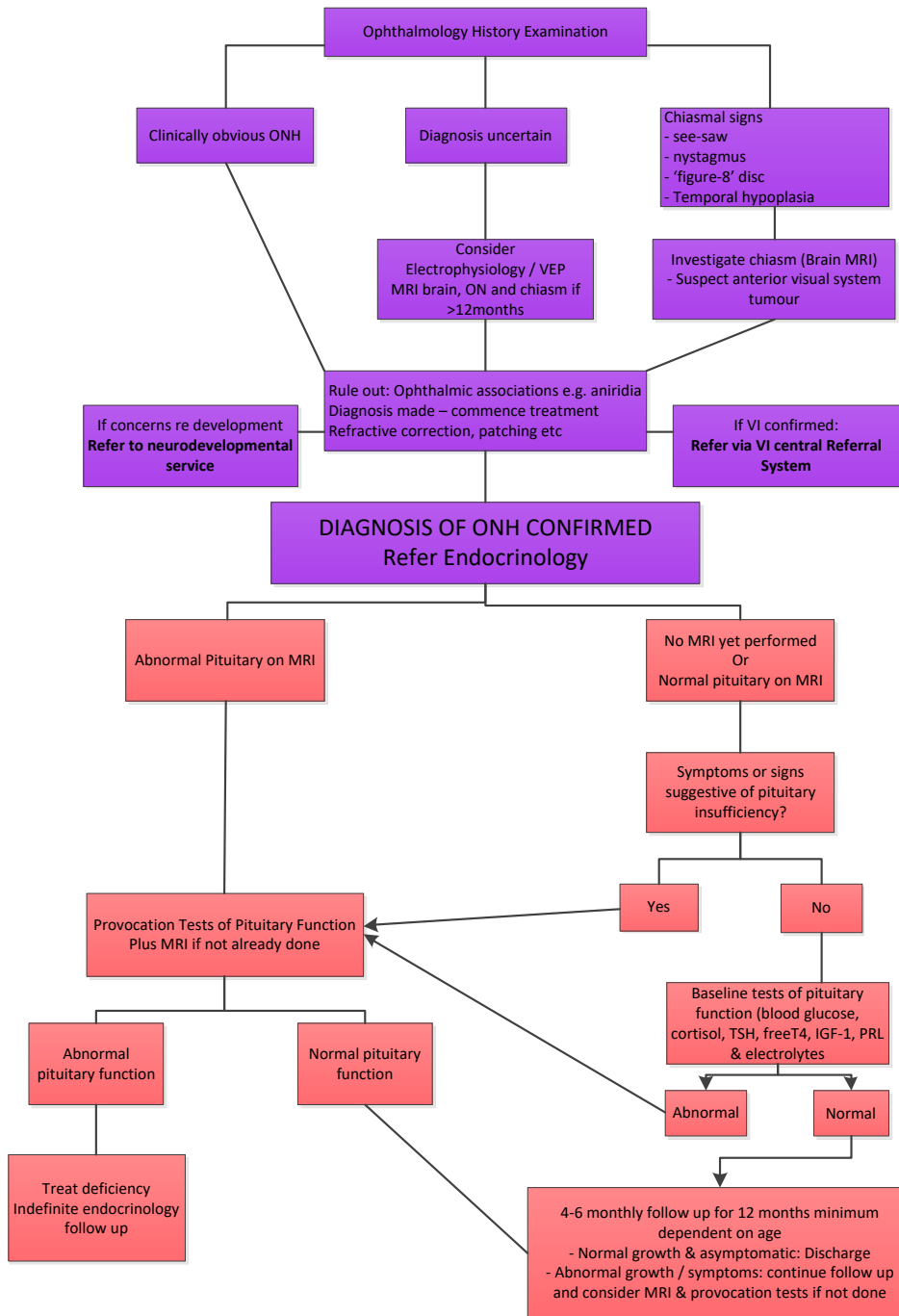
*This guideline is not intended to be construed or to serve as a standard of care. Standards of care are determined on the basis of all clinical data available for an individual case and are subject to change as scientific knowledge and technology advance and patterns of care evolve. Adherence to guideline recommendations will not ensure a successful outcome in every case, nor should they be construed as including all proper methods of care or excluding other acceptable methods of care aimed at the same results. The ultimate judgement must be made by the appropriate healthcare professional(s) responsible for clinical decisions regarding a particular clinical procedure or treatment plan. This judgement should only be arrived at following discussion of the options with the patient, covering the diagnostic and treatment choices available. It is advised, however, that significant departures from the national guideline or any local guidelines derived from it should be fully documented in the patient's case notes at the time the relevant decision is taken.*

# Visual Impairment Network for Children and Young People (VINCYP)

Specialist Healthcare Commissioning



## VINCYP / Scottish Paediatric Endocrine Group Optic Nerve Hypoplasia Diagnostic and Investigative Pathway (NSD610-021.08)



## Visual Impairment Network for Children and Young People (VINCYP)

### References

1. Taylor D. Optic nerve axons: life and death before birth. *Eye* 2005;19:499-527
2. Garcia ML, Ty EB et al. Systemic and ocular findings in 100 patients with optic nerve hypoplasia. *Journal of Childhood Neurology* 2006;21(11):949-956
3. Tornqvist K, Ericsson A, Kellen B. Optic nerve hypoplasia: risk factors and epidemiology. *Acta Ophthalmol Scand* 2002;80:300-304
4. Siatowski RM, Sanchez JC et al. The clinical, neuroradiographic, and endocrinological profile of patients with bilateral optic nerve hypoplasia. *Ophthalmology* 1997 Mar; 104(3):493-6
5. Hoyt C. and Taylor D. *Pediatric Ophthalmology and Strabismus*. Elsevier 2013. ISBN 9781455737819
6. Dutton GN. Congenital disorders of the optic nerve: excavations and hypoplasia. *Eye* 2004;18:1038-48
7. Jacobson L, Hällstrom A, Flodmark O. Large cups in normal size discs: a variant of optic nerve hypoplasia in children with periventricular leucomalacia. *Arch Ophthalmol* 1997;115:1263-1269
8. Birkebaek NH, Patel L et al. Optic nerve size evaluated by magnetic resonance imaging in children with optic nerve hypoplasia, multiple pituitary hormone deficiency, isolated growth hormone deficiency and idiopathic short stature. *J Pediatr* 2004;145:536-41
9. Weiss AH, Kelly JP. Acuity, ophthalmoscopy, and visually evoked potentials in the prediction of visual outcome in infants with bilateral optic nerve hypoplasia. *J AAPOS* 2003 Apr;7(2):108-115
10. (Mehta A, Hindmarsh PC et al. Congenital hypopituitarism : clinical ,molecular and neuroradiological correlates. *Clin. Endocrinol* 2009;71:376-382
11. Deal C, Hasselmann C et al. Associations between pituitary imaging abnormalities and clinical and biochemical phenotypes in children with congenital growth hormone deficiency : data from an international observational study. *Horm Res* 2013;79:283-292
12. Chen SC, McDevitt H et al. Early Identification of Pituitary Dysfunction in Congenital Nasal Pyriform Aperture Stenosis : recommendations Based on Experience in a Single Centre. *Horm Res Paediatr* 2015 ; 83 : 302 -310)